

Quantitative and Automatic Echographic Monitoring of Labor Progression

S. Casciaro, F. Conversano, E. Casciaro, G. Soloperto
National Research Council
Institute of Clinical Physiology
Lecce, Italy
sergio.casciaro@cnr.it

M. Stark
The New European Surgical Academy
Berlin, Germany

A. Perrone
Obstetrics and Gynecology Department
Vito Fazzi Hospital
Lecce, Italy

Abstract— Nowadays the decision between Caesarean Sections (CS), natural or operative child delivery is taken upon interpretation of manually measured anatomical parameters and recorded fetal heart rate, exposing the clinical staff and patients to human errors and determining the continuously rising rate of CS above the ideal 15% recommended by the World Health Organization. This study introduces a new method for non-invasive, quantitative and automatic monitoring of childbirth labor progression. We combined an ultrasound system with a real-time tracking algorithm in order to automatically measure labor progression parameters, like head station, head position, progression angle, based on patient specific anatomical references [Patent no. PCT/EP2009/008321]. A 2D digital echograph connected to a PC for real-time image processing was employed to measure fetal head station (FHS) and progression angle (PA). A quantitative validation study was carried out on a birth simulator, consisting of fetal and maternal mannequins immersed in water. Then, a preliminary intrapartum B-mode imaging study was conducted on patients by means of the developed methods and corresponding algorithms. In the birth simulator, the automatic identification was correct in 98% of the computed images providing high visual reliability for the operator. The average errors (expressed as bias \pm SD) were 0.8 \pm 1.9 mm for FHS and 3 $^{\circ}$ \pm 4 $^{\circ}$ for the PA. Accuracies improve of about 30% by reducing the frame-rate to be processed, i.e. from 1 fps to 0.2 fps, which is still suitable for the purpose. The methodology has been successfully validated in preliminary intrapartum echographic monitoring.

Keywords— *Ultrasonic imaging; biomedical signal processing; pregnancy; clinical diagnosis; childbirth; labor monitoring.*

I. INTRODUCTION

Childbirth labor is divided into three stages and lasts on average from 12 to 17 hours; monitoring its progression requires great efforts and attention for labor attendants to each and every parturient. Specifically, intra-partum assessment of progression indicators (cervical dilatation, fetal head station (FHS) and rotation, progression angle (PA), etc.) is essential for the proper management of labor and may address to surgical (i.e., Caesarean Section) or an operative intervention

(i.e., application of forceps or vacuum extractor), rather than natural delivery. Assessments of these parameters are currently performed by highly subjective trans-vaginal manual inspections, although relevant literature extensively reported evidences of unreliability of manual pelvic examinations. Referring, for instance, to FHS determination, a recent study, quantitatively assessing this skill on a pelvis model in 32 experienced clinicians, returned an error percentage always between 50% and 88%, depending on the considered FHS, with a 26% of cases in which a “high” station was misdiagnosed as a “mid” station, with potential major implications in the management of the corresponding patients [1]. Similarly, the performance of clinicians in measuring cervical dilatation on cervix models, proved that in about 50% of cases the evaluation error was higher than 1 cm [2],[3].

Labor management, as any other medical decision, should rarely be approached without the use of diagnostic imaging. Regardless the undisputable value of techniques such as computed tomography (CT), magnetic resonance imaging (MRI), and contrast enhanced ultrasound (US) [4]-[11], conventional US remains the best suited method for safe and real-time childbirth related diagnostic purposes as it uses non-ionizing radiation and is widely available, relatively inexpensive and highly tolerated by the patients, offering also unique intraoperative guidance features [12]-[16].

Exploiting such capabilities of echographic imaging, different studies compared the clinical intrapartum assessment of fetal head rotation by transvaginal manual examination with the corresponding value determined by US imaging of the fetal head: the rate of error was 67% during the first labor stage [17] and 45% during the second labor stage [18], even if fetal head rotation at manual examination was recorded as correct when reported within \pm 45 degrees of the ultrasound assessment. Although translabial [19] and transabdominal [20] US imaging performed during labor provides a valuable contribution to its managing, echographs are scarcely involved in evaluating the indicators of partum progression.

The most concerning consequence of such indeterminateness in labor managing and lack of objective evidences in support of clinician choices is the currently unacceptable rate of Caesarean Sections (CS) (Europe: 24%; USA: 29%; Italy: 38%; South Italy: 52%), largely above the value of 15% recommended by the World Health Organization [21].

Aim of this study was to introduce a new method for non-invasive, quantitative and automatic monitoring of childbirth labor. This method has the potential to overcome the mentioned limits of current techniques, since all measurements rely on a non-invasive ultrasound system combined with advanced real-time tracking algorithms, capable of automatically measuring the labor progression based on patient specific anatomical references [22]. In particular, the long term goal of our work is to provide the possibility of simultaneous real-time measurements of several key parameters indicating labor progress, like head station, head position, progression angle, cervical dilatation and shape, shoulder position.

II. MATERIALS AND METHODS

We combined an ultrasound system with a real-time tracking algorithm in order to automatically measure labor progression parameters, like head station, head position, progression angle, based on patient specific anatomical references (Patent no. PCT/EP2009/008321) [22].

A 2D digital echograph connected to a PC for real-time image processing was employed to measure fetal head station (FHS) and progression angle (PA). A quantitative validation study was carried out on a birth simulator (details of the experimental set-up are provided in Section II.A). Then, a preliminary intrapartum B-mode imaging study (Section II. B) was conducted on patients by means of the developed methods and corresponding algorithm.

A. Birth simulator experiments

We developed an experimental set-up to reproduce the expected working conditions of an ultrasound probe adherent to the pubic area of the body of a parturient and linked to an echographic device for signal acquisition, data processing and result display.

A 2D convex ultrasound transducer (CA631, Esaote Spa, Florence, Italy) connected to a last generation digital echograph (MyLab70 XVG, Esaote Spa, Florence, Italy) was used for echographic imaging of a birth simulator. This mechanical device consisted of the maternal mannequin and the fetal head. The first was realized by means of 3D stereolithography of a standardized pubic bone [23] in polymeric resin, provided with a symphysis realized in acrylic gel, in order to mimic the cartilaginous tissue. The fetal head was simulated by a solid, obtained as the rotation of an ellipse whose axes corresponded to the occipitomeatal and bitemporal typical diameters [24] (major axis: 12.5 cm; minor axis: 8 cm), in a tissue mimicking cellulose based hydrogel [25]-[27]. The whole set-up was

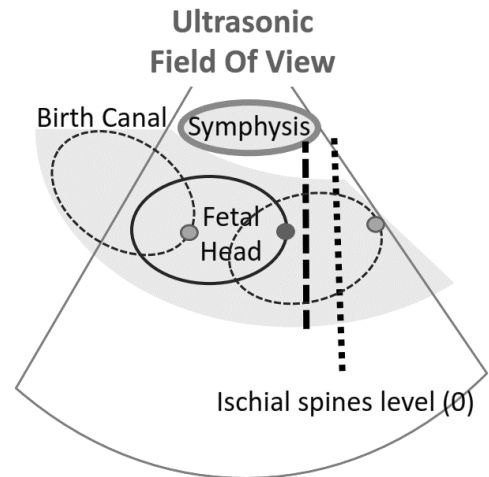


Figure 1. Schematic diagram of the experimental set-up adopted for assessment of tracking accuracy. By positioning the fetal head at different locations in the space comprised within the maternal pubic bone (birth canal), different stages of labor were simulated and relative position of the fetal head apex and distal end of the symphysis were evaluated in terms of FHS and PA.

immersed in a water bath, in order to avoid the presence of air among the different birth simulator components.

The fetal head was moved along its typical trajectory within the birth canal (Fig. 1) and the position of its apex was tracked with respect to the distal end of the symphysis, by an in-house developed algorithm [28] adapted to this specific application.

B. Intrapartum study

Women were considered eligible for participation if they fulfilled the following criteria: singleton pregnancy; cephalic presentation; non obese women; gestation longer or equal to 36 completed weeks; no known major fetal malformation; uncomplicated pregnancy; in active labor but not in active second stage (cervix dilatation <10 cm); clinical decision made to perform continuous cardiotocography monitoring. Patients are under 16 years of age or unable to provide written informed consent were not included. Echographic monitoring of the woman in labor was performed by translabial longitudinal positioning of the US probe, whose relative position and orientation was consistent with the scheme validated in vitro (i.e. ultrasonic field of view centered on the symphysis); B-mode US 5-s clips were acquired every other contractions and, for each clip, the image more univocally showing the validated landmarks (fetal head apex and distal end of the symphysis) was selected for feeding the tracking algorithm in order to calculate FHS and PA. Simultaneously, cervix dilatation, as measured by the attending clinical staff, was also recorded.

III. RESULTS AND DISCUSSION

For each considered probe placement, couples of anatomical reference points were chosen by an operator on the initial echographic image, then the fetal mannequin was moved following a pre-established sequence of locations, including all possible values of fetal head station and position (according to the corresponding definitions provided by the American

College of Obstetricians and Gynecologists) and several combinations of possible occiput presentations (anterior-posterior, left-right, etc.). B-mode echographic image frames were acquired for the whole duration of described experiments, for a total of about 4,000 images. US frames were real-time processed by means of the new algorithm, dedicated to pattern tracking and calculation of corresponding mutual distances and angles between fetal head apex and distal end of the symphysis.

In the birth simulator, the automatic identification was correct in 98% of the computed images providing high visual reliability for the operator. The average errors (expressed as bias±SD) were 0.8±1.9 mm for FHS and 3°±4° for the PA. Accuracies improve of about 30% by reducing the frame-rate to be processed, i.e. from 1 fps to 0.2 fps, which is still suitable for the purpose.

The methodology has been successfully translated in preliminary intrapartum echographic study. Recently, various attempts have been made to design instruments for improving accuracy of cervical dilatation and fetal head station [29]-[32] measurement, but none of them introduced significant advantages and some showed highly invasiveness for mothers and babies [33]. As opposite, our methodology, tested for labor monitoring on a number of volunteers, resulted well tolerated by the patients. Pubic symphysis resulted always recognizable in the acquired US imaged, thus easily identified by the tracking algorithm. Fetal head outline appeared instead discontinuous, especially for those portion of the fetal skull located underneath the pubic bone, as the latter, conversely than cartilage (i.e. symphysis), attenuates US waves, thus image contrast, in the underlying structures. Nonetheless, the tracking algorithm successfully interpolated fetal head outline and derived apex coordinates as well as the location of the distal end of the symphysis (Fig. 2a-c). Automatic measurement of PA was performed (Fig. 2d) throughout labor duration and FHS was evaluated.

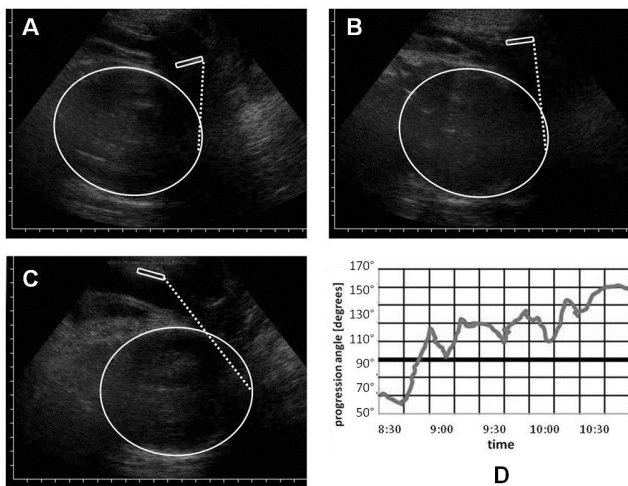


Figure 2. Example of US Images (a-c) at different stages of labor and plot of PA during labor.

Future studies will include the repetition of similar experiments employing a 3D ultrasound probe, whose field of view will allow the simultaneous measurement of both fetal head station and rotation (and also of other labor parameters that were not considered in this study).

Finally, our methodology could respond to the needs of new standardized quantitative monitoring approaches and new guidelines to reduce the rate of CS and connected risks [34], overcoming the limitations in clinician ability to manually measure the labor progress and providing documentation records of objective parameters, in support of clinical choices for potential legal litigations (related to possible damages suffered by the patient and/or the baby as a consequence of an inadequate labor management).

IV. CONCLUSIONS

The study demonstrated the effectiveness of using quantitative ultrasound methods and automatic tracking algorithms for real-time non-ionizing monitoring of labor progress. Moreover, the studies conducted on the in vitro set-up were also useful to quantify the accuracy of the newly developed approach. The clinical translation of the methodology was proven feasible and examined patients did not incur discomfort, thus US acquisitions could be safely performed during all phases of labor.

Therefore, this new objective approach to childbirth labor monitoring could make available a significant amount of information with respect to the current state of the art, and, in particular, it is expected to dramatically reduce not only the invasiveness compared to other methods, but also the difficulties for operators and the possible source of errors and subsequent risks. In fact, timely recognition of abnormal labor patterns will be possible, so representing a tool for earlier diagnosis and a support for operative child birth or CS prescriptions, allowing also their punctual documentation.

REFERENCES

- [1] O. Dupuis, R. Silveira, A. Zentner, A. Dittmar, P. Gaucherand, M. Cucherat, T. Redarce, and R. C. Rudigoz, "Birth simulator: reliability of transvaginal assessment of fetal head station as defined by the American College of Obstetricians and Gynecologists classification," *Am. J. Obstet. Gynecol.*, vol. 192, no. 3, pp.868-874, March 2005.
- [2] J. Y. Phelps, K. Higby, M. H. Smyth, J. A. Ward, F. Arredondo, and A. R. Mayer, "Accuracy and intraobserver variability of simulated cervical dilatation measurements," *Am. J. Obstet. Gynecol.*, vol. 173, no. 3, pp. 942-945, September 1995
- [3] D. J. Tuffnell, F. Bryce, N. Johnson, and R.J. Lilford, "Simulation of cervical changes in labour: reproducibility of expert assessment," *Lancet*, vol. 2, no. 8671, pp. 1089-1090, November 1989.
- [4] M. Claudon, D. Cosgrove, T. Albrecht, L. Bolondi, M. Bosio, F. Calliada, J.M. Correias, K. Darge, C. Dietrich, M. D'Onofrio, D.H. Evans, C. Filice, L. Greiner, K. Jäger, N. Jong, E. Leen, R. Lencioni, D. Lindsell, A. Martegani, S. Meairs, C. Nolsøe, F. Piscaglia, P. Ricci, G. Seidel, B. Skjoldbye, L. Solbiati, L. Thorelius, F. Tranquart, H.P. Weskott, T. Whittingham, "Guidelines and good clinical practice recommendations for contrast enhanced ultrasound (CEUS) - update 2008," *Ultraschall Med*, vol. 29, pp. 28-44, February 2008.
- [5] S. Casciaro, F. Conversano, A. Ragusa, M.A. Malvindi, R. Franchini, A. Greco, T. Pellegrino, G. Gigli, "Optimal enhancement configuration of silica nanoparticles for ultrasound imaging and automatic detection at

- conventional diagnostic frequencies," *Invest Radiol*;45(11) pp.715-724, November 2010.
- [6] G. Soloperto and S. Casciaro, "Progress in atherosclerotic plaque imaging," *World J Radiol.*, vol. 4, no. 8, pp. 353-371, August 2012.
- [7] T.K. Kim, B.I. Choi, J.K. Han, H.S. Hong, S.H. Park, S.G. Moon, "Hepatic tumors: contrast agent-enhancement patterns with pulse-inversion harmonic US," *Radiology*, vol. 216:pp. 411-7. August 2000.
- [8] S. Casciaro, "Theranostic applications: Non-ionizing cellular and molecular imaging through innovative nanosystems for early diagnosis and therapy," *World J Radiol*, vol. 3, pp. 249-55, October 2011.
- [9] T. Murakami, Y. Imai, M. Okada, T. Hyodo, W.J. Lee, M.J. Kim, T. Kim, B.I. Choi, "Ultrasonography, computed tomography and magnetic resonance imaging of hepatocellular carcinoma: toward improved treatment decisions," *Oncology*, vol. 81, Suppl 1, pp. 86-99, December 2011.
- [10] A. Sciarra, J. Barentsz, A. Bjartell, J. Eastham, H. Hricak, V. Panebianco, J.A. Witjes, "Advances in magnetic resonance imaging: how they are changing the management of prostate cancer," *Eur Urol*, vol. 59, pp. 962-77, June 2011;
- [11] A. Qayyum, "MR spectroscopy of the liver: principles and clinical applications," *Radiographics*, vol. 29, pp. 1653-64, October 2009.
- [12] M. A. Malvindi, A. Greco, F. Conversano, A. Figuerola, M. Corti, M. Bonora, A. Lascialfari, H. A. Doumari, M. Moscardini, R. Cingolani, G. Gigli, S. Casciaro, T. Pellegrino, and A. Ragusa, "Magnetic/silica nanocomposites as dual-mode contrast agents for combined magnetic resonance imaging and ultrasonography", *Adv. Funct. Mater.*, vol. 21, pp. 2548-2555, July 2011.
- [13] F. Conversano, A. Greco, E. Casciaro, A. Ragusa, A. Lay-Ekuakille, and S. Casciaro, "Harmonic Ultrasound Imaging of Nanosized Contrast Agents for Multimodal Molecular Diagnoses," *IEEE Trans. Instrum. Meas.*, vol. 61, no. 7, pp. 1848-1856, July 2012.
- [14] F. Conversano, G. Soloperto, A. Greco, A. Ragusa, E. Casciaro, F. Chiriaco, C. Demitri, G. Gigli, A. Maffezzoli, and S. Casciaro, "Ecographic detectability of optoacoustic signals from low-concentration PEG-coated gold nanorods," *Int. J. Nanomedicine*, vol. 7, pp. 4373-89, August 2012.
- [15] A. Tinelli, A. Malvasi, A. J. Schneider, J. Keckstein, G. Hudelist, M. Barbic, S. Casciaro, G. Giorda, R. Tinelli, Perrone A, F.G. Tinelli, "First abdominal access in gynecological laparoscopy: which method to utilize?," *Minerva Ginecol*, vol 58, pp 429-40, October 2006.
- [16] P. Lamata, F.Lamata, V. Sojar, P. Makowski, L. Massoptier, S. Casciaro, W. Ali, T. Stüdeli, J. Declerck, O.J. Elle, B. Edwin, "Use of the Resection Map system as guidance during hepatectomy," *Surg Endosc*, vol. 24, pp. 2327-37, September 2010
- [17] D. M. Sherer, M. Miodovnik, K. S. Bradley, and O. Langer, "Intrapartum fetal head position I: comparison between transvaginal digital examination and transabdominal ultrasound assessment during the active stage of labor," *Ultrasound. Obstet. Gynecol.*, vol. 19, no. 3, pp. 258-263, March 2002.
- [18] D. M. Sherer, M. Miodovnik, K.S. Bradley, and O. Langer, "Intrapartum fetal head position II: comparison between transvaginal digital examination and transabdominal ultrasound assessment during the second stage of labor," *Ultrasound. Obstet. Gynecol.*, vol. 19, no. 3, pp. 264-268, March 2002.
- [19] W. L. Lau, L. Y. Cho, W. C. Leung, "Intrapartum translabial ultrasound demonstration of face presentation during first stage of labor," *J. Obstet Gynaecol. Res.*, vol. 37, no. 12, pp.1868-71, December 2011.
- [20] A. Malvasi, A. Tinelli, A. Brizzi, M. Guido, F. Laterza, G. De Nunzio, M. Bochicchio, T. Ghi, M. Stark, D. Benhamou, G. C. Di Renzo, "Intrapartum sonography head transverse and asynclitic diagnosis with and without epidural analgesia initiated early during the first stage of labor," *Eur. Rev. Med. Pharmacol. Sci.*, vol. 15, no. 5, pp. 518-23, May 2011.
- [21] A. Malvasi, A. Tinelli, M. Guido, A. Zizza, G. Cotrino, and U. Vergari, "The increasing trend in cesarean sections in south eastern Italy: medical and biopolitical analysis of causes and possible mechanisms for its reduction," *Curr. Women Health Rev.*, vol. 5, no. 3, pp. 176-183, March 2009.
- [22] S. Casciaro, F. Conversano, E. Casciaro, "Ultrasonic apparatus for measuring a labor progress parameter" Patent Application PCT/EP2009/008321.
- [23] W. Heinrich, J. Dudenhausen, I. Fuchs, A. Kamena, and B. Tutschek, "Intrapartum translabial ultrasound (ITU): sonographic landmarks and correlation with successful vacuum extraction," *Ultrasound Obstet Gynecol.*, vol. 28, no. 6, pp. 753-760, November 2006.
- [24] S. Cox, C. Werner, B. Hoffman, F. Cunningham, Williams Obstetrics 22nd Edition Study Guide, McGraw-Hill, 2005.
- [25] S. Casciaro, F. Conversano, S. Musio, E. Casciaro, C. Demitri, and A. Sannino, "Full experimental modelling of a liver tissue mimicking phantom for medical ultrasound studies employing different hydrogels," *J. Mater. Sci. Mater. Med.*, vol. 20, no. 4, pp. 983-989, April 2009.
- [26] S. Casciaro, C. Demitri, F. Conversano, E. Casciaro, and A. Distante, "Experimental investigation and theoretical modelling of nonlinear acoustical behaviour of a liver tissue and comparison with a tissue mimicking gel," *J. Mater. Sci. Mater. Med.*, vol. 19, pp. 899-906, February 2008.
- [27] C. Demitri, A. Sannino, F. Conversano, S. Casciaro, A. Distante, A. Maffezzoli, "Hydrogel based tissue mimicking phantom for in-vitro ultrasound contrast agents studies," *J Biomed Mater Res B Appl Biomater.*, vol. 87, no. 2, pp.338-45, November 2008.
- [28] F. Conversano, E. Casciaro, R. Franchini, A. Lay-Ekuakille, and S. Casciaro, "A quantitative and automatic echographic method for real-time localization of endovascular devices" *Trans. Ultrason. Ferroelectr. Freq. Control.*, vol 58, no. 10, pp.2107-17, October 2011.
- [29] M. Letić, "Inaccuracy in cervical dilatation assessment and the progress of labour monitoring," *Med Hypotheses*, vol. 60, no. 2, pp. 199-201, February 2003.
- [30] R. S. Lucidi, L. A. Blumenfeld, and R. A. Chez, "Cervimetry: a review of methods for measuring cervical dilatation during labor," *Obstet. Gynecol. Surv.*, vol. 55, no. 5, pp. 312-320, May 2000.
- [31] M. C. Antonucci, M. C. Pitman, T. Eid, P. J. Steer, E. S. Genevier, "Simultaneous monitoring of head-to-cervix forces, intrauterine pressure and cervical dilatation during labour," *Med. Eng. Phys.*, vol. 19, no. 4, pp. 317-326, June 1997.
- [32] H. J. van Dessel, J. H. Frijns, F. T. Kok, and H. C. Wallenburg, "Ultrasound assessment of cervical dynamics during the first stage of labor," *Eur. J. Obstet. Gynecol. Reprod. Biol.*, vol. 53, no. 2, pp.123-127, February 1994.
- [33] O. Barnea, O. Luria, A. Jaffa, M. Stark, H. E. Fox, and D. Farine, "Relations between fetal head descent and cervical dilatation during individual uterine contractions in the active stage of labor," *J. Obstet. Gynaecol. Res.*, vol. 35, no. 4, pp. 654-659, August 2009.
- [34] A. Malvasi, A. Tinelli, G. Serio, R. Tinelli, S. Casciaro, C. Cavallotti, "Comparison between the use of the Joel-Cohen incision and its modification during Stark's cesarean section," *J Matern Fetal Neonatal Med.*, vol. 20, no.10, pp. 757-61, October 2007.